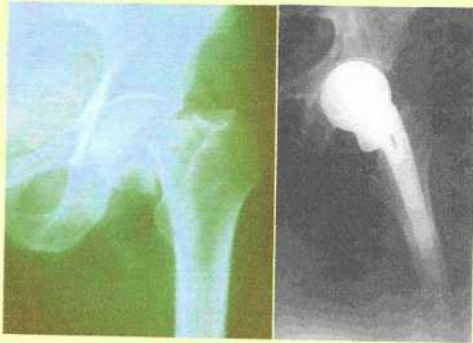
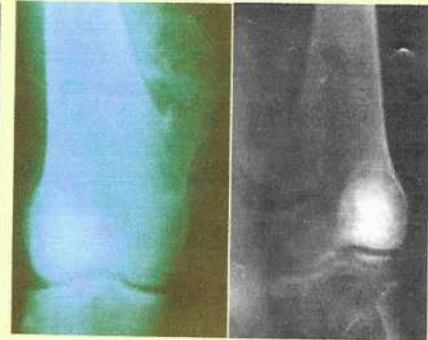
**SOME SURGERY OR C.M.R. CASES DONE BY  
DR. JIMMY M. L. DURING 2012 – 2013 PERIOD**



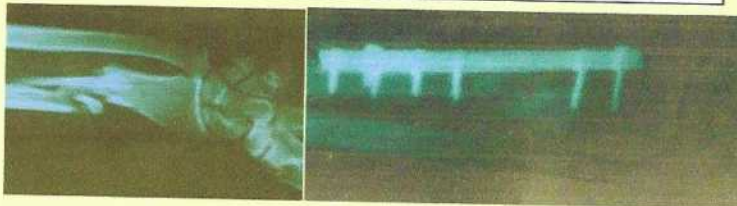
Hip prosthesis done for fracture neck of femur, Kunji Pathumma, 76 years

Exostosis  
tumour  
of femur  
bone  
excised,  
Honey  
Mol, 22  
years

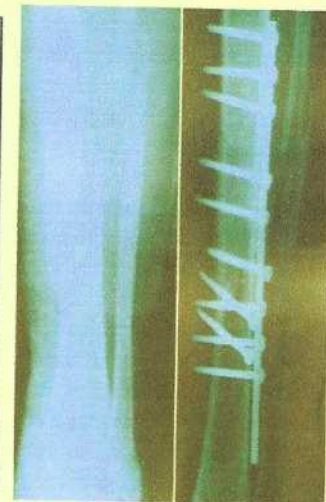

**ORTHOPAEDIC SURGERY REPORTS**

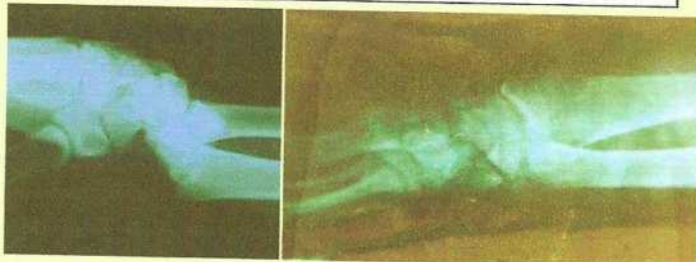
Communitated fracture radius of left forearm done with ORIF  
Plating surgery and iliac crest bone grafting, Afsal, 26 years



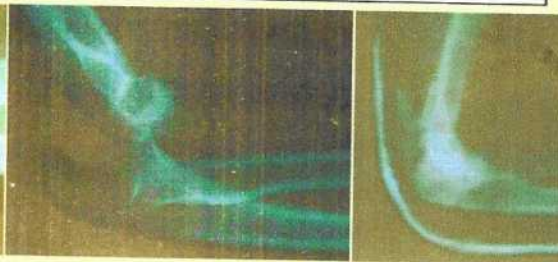
Fracture  
tibia of  
left leg  
done  
with  
ORIF  
Plating  
surgery,  
Eusef,  
42 years



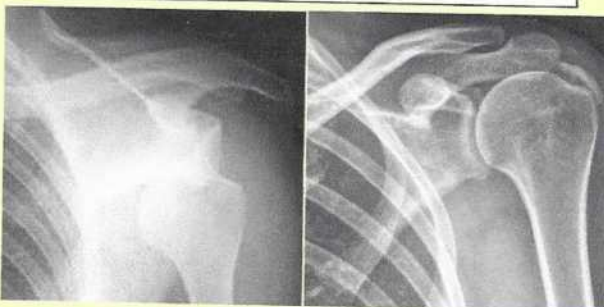Displaced communitated colle's fracture wrist  
perfectly reduced by C.M.R., Fathima, 62 years




Posterior dislocation of elbow reduced by  
C.M.R., Saraswathy Amma, 56 years



Anterior dislocation of shoulder reduced by  
C.M.R., Kunji Pathumma, 76 years

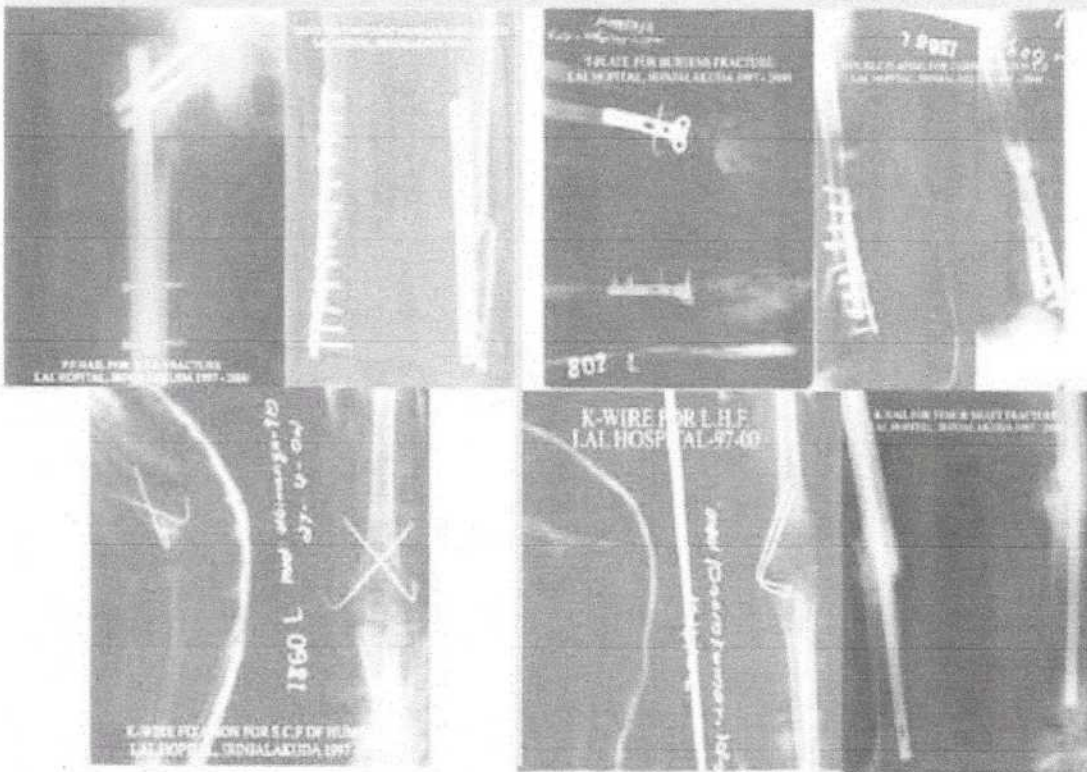


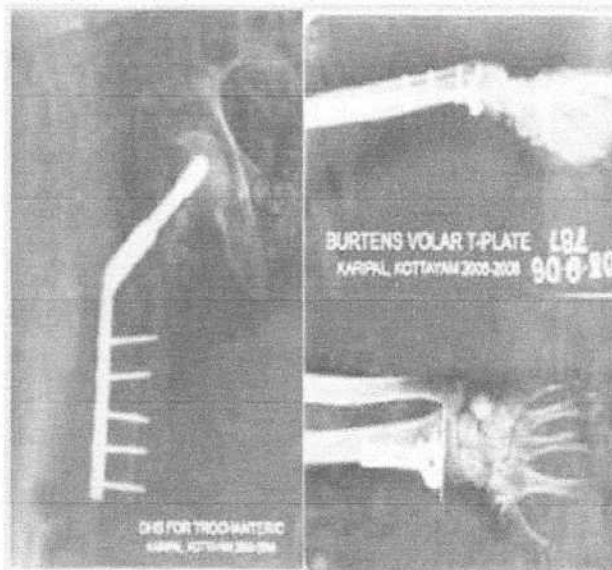**Dr. Jimmy M. L., MBBS, D – Ortho, WOEP, FASIF(Switzerland), DNB Ortho, PGD Guidance and Counselling, PGD HRM, M.A. Disaster Management, MBA(IB), Orthopaedic Surgeon, Past state I.T. and Joint Secretary of Kerala orthopaedic association, Past IMA Joint Secretary, Past orthopaedic surgeon at L.F. Mission hospital, Angamaly, Medical College, Kottayam and MBMM hospital, Kothamangalam. Contact - Mob; 9446441698, 9946012740, 8802269814, For surgical reports; doctorjimmy.net, youtube.com/ jimmyml2000, facebook.com/jimmymoyalalan**



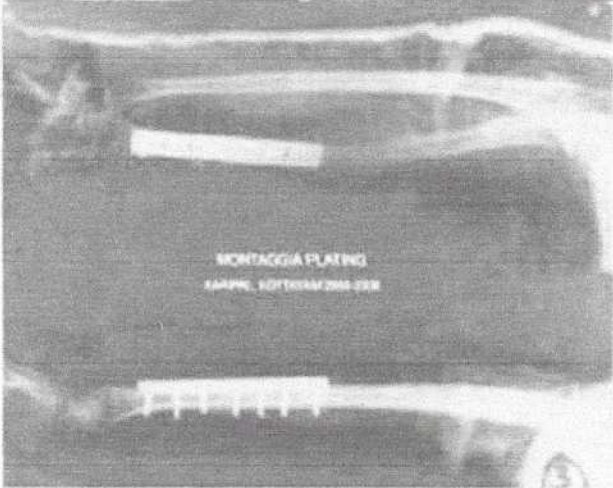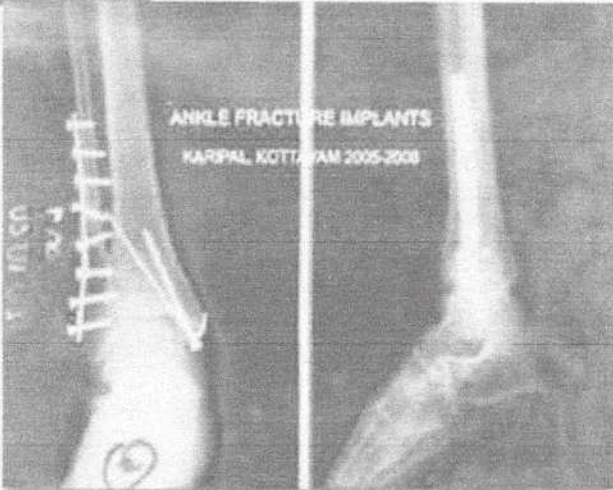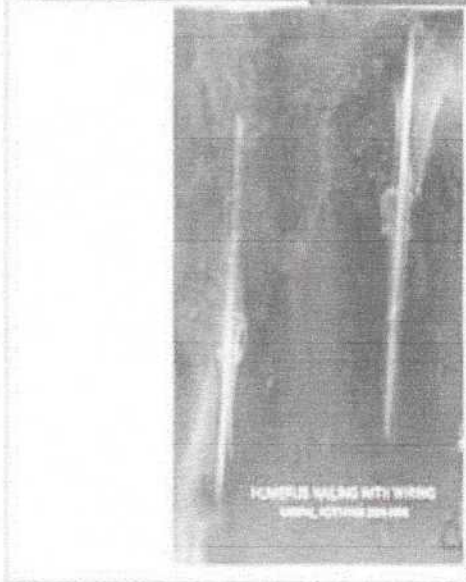
IV. ഡോ. ജിമ്മി ചെയ്ത ചില ശസ്ത്രക്രിയകളുടെ ഏക്സറേകൾ  
 a). ലാൽ ആശുപത്രിയിലെ I, II, III

1999 - 2002 PERIOD  
 DONE BY DR. JIMMY M. L.  
 13 TO 11 YEARS BACK  
 MODERN NAILS, PLATS

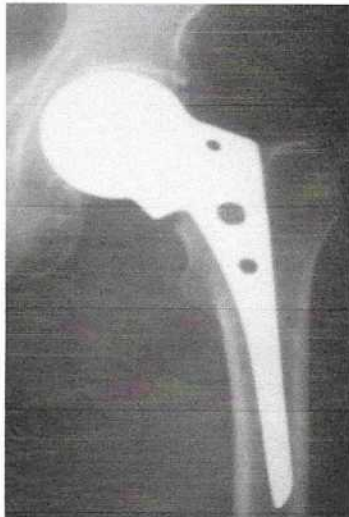




IV. ഡോ. ജിമ്മി ചെയ്ത ചില  
 ശസ്ത്രക്രിയകളുടെ എക്സ്റേകൾ  
 b) കരിപ്പാൽ ആശുപത്രിയിലെ IV, V  
 2004 - 2009 PERIOD  
 DONE BY DR. JIMMY M. L.  
 9 TO 4 YEARS BACK  
 MODERN NAILS, PLATS



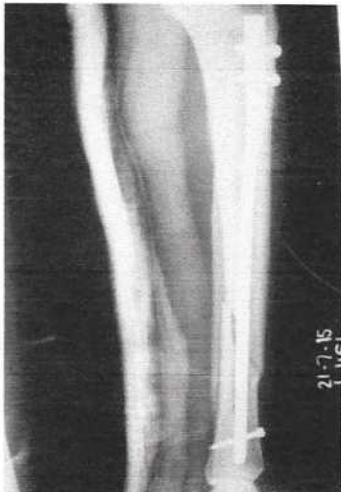**JUNE – JULY 2015 SURGICAL X – RAYS : DONE BY DR. JIMMY M. L. AND TEAM  
AT IDUKKI DISTRICT CO-OPERATIVE HOSPITAL, THODUPUZHA – PAGE 1**



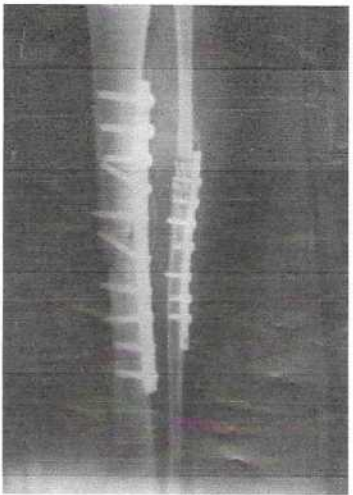**HEMI ARTHROPLASTY HIP  
KUNJUMOL, 60**



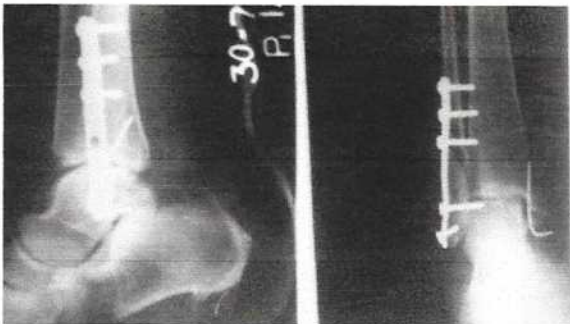**DYNAMIC HIP SCREW : DHS  
SARAMMA, 93**



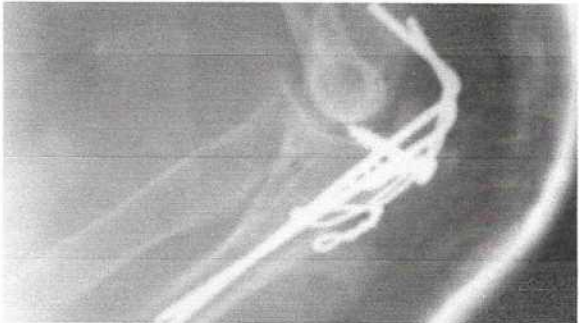**INTER LOCKING NAIL TIBIA  
RAJU, 32**



**PLATING BOTH BONE LEG  
RAKESH, 22**

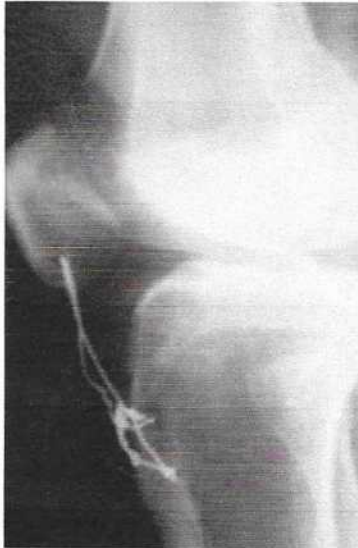


**ANKLE BI MALLEOLAR FIX  
MARY FRANCIS, 58**

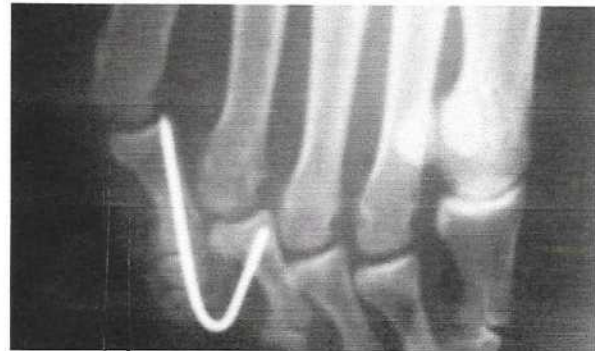

**ELBOW OLECRANON WIRE  
RUGMINI, 85**

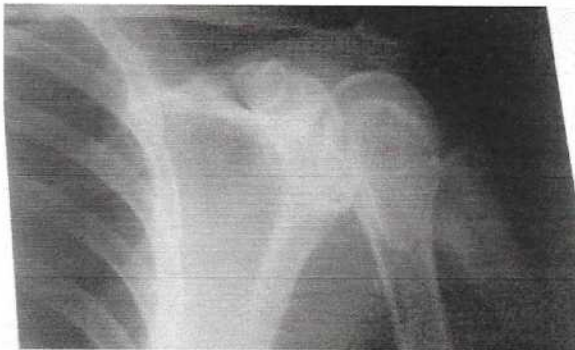**JUNE – JULY 2015 SURGICAL X – RAYS : DONE BY DR. JIMMY M. L. AND TEAM  
AT IDUKKI DISTRICT CO-OPERATIVE HOSPITAL, THODUPUZHA – PAGE 2**



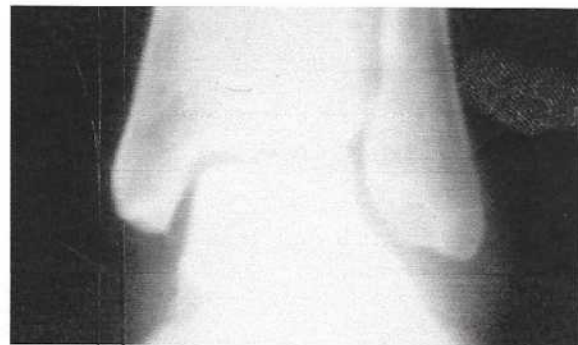**KNEE PATELLA TENDON WIREING – JIJO, 33**



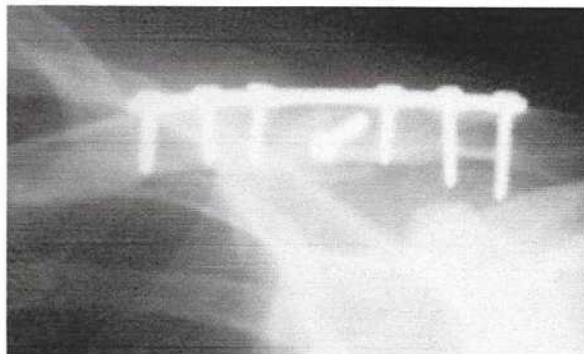
**TOE FRACTURE K WIRE FIX – RENJITH, 19**



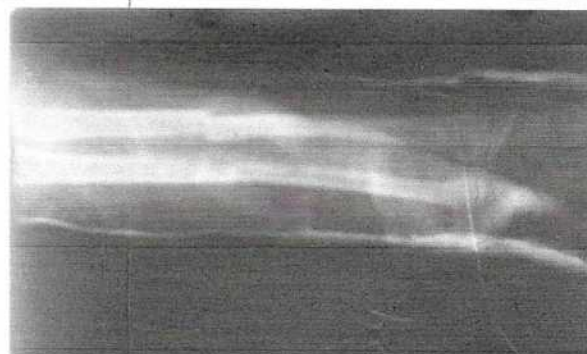
**BICEPS TENDON ANCHORING – GEORGE, 55**



**SINOVECTOMY ANKLE – KOMALAM, 48**



**CLAVICLE IMPLANT REMOVAL – ANJSH, 25**



**FOREARM B.B. C.M.R. - ADIL, 12**